

Use of Nape and Peri-Auricular Hair by Follicular Unit Extraction to Create Soft Hairlines and Temples: My Experience With 128 Patients

Aesthetic Surgery Journal
2015, 1–7
© 2015 The American Society for
Aesthetic Plastic Surgery, Inc.
Reprints and permission:
journals.permissions@oup.com
DOI: 10.1093/asj/sjv137
www.aestheticsurgeryjournal.com
OXFORD
UNIVERSITY PRESS

Sanusi Umar, MD

Abstract

Background: Hairlines and temples can look unnatural due to coarseness of the safe donor area of transplanted scalp hair. Although the thinner caliber of nape and peri-auricular (NPA) hair would be ideal to create softer hairlines, they have not been used mainly because of concerns that they are nonpermanent.

Objective: We assessed the outcome of NPA hair transplanted to hairlines and temples in selected patients.

Methods: During November 2006 to November 2011, follicular unit extraction (FUE) transplantation using NPA hair was conducted in 128 patients following a shave test involving the visual evaluation of hair density and caliber of shaved head donor areas. The test was used to determine permanent versus nonpermanent donor areas. A questionnaire was sent to patients to assess satisfaction with their restored hairlines, with a follow-up questionnaire sent to those who initially responded.

Results: Three-quarters of patients are good candidates for use of NPA hair to the hairlines and temples based on the shave test. Of 128 patients transplanted, 71% responded and reported a mean overall satisfaction of 8.3 (scale, 1-10). Patients saw full hair coverage at the recipient area at a mean of 9.6 months after surgery. Nineteen patients reported lost grafts. Thirty-three patients responded to a second survey and reported a mean overall satisfaction of 8.5 at an average of 4.6 years after surgery; only 5 (15%) new instances of graft loss were reported.

Conclusions: Soft, natural-looking hairlines can be created in select patients using NPA hair as a donor source by FUE hair transplantation.

Level of Evidence: 4

Accepted for publication June 10, 2015.



Swinehart¹ astutely pointed out that the hairline is not really a line at all, but rather a zone in which hairs become progressively finer and less dense until bare forehead skin is apparent. Unless this situation is mimicked in a transplanted hairline, which most often approximates a Norwood class 2 or 3 recession in males, the result has the potential to look unnatural. Traditionally, hair from the safe donor area (SDA) of the scalp, a horizontal region located in the middle zone of the occipital and parietal areas, is used to create a more blended hairline despite the limitations of a larger follicle diameter than scalp hair elsewhere. Moreover, in individuals possessing thick hair (such as Asians) and those with darker hair color and a contrasting light skin tone, it is

a challenge to craft a natural-looking soft hairline. One approach to improve this situation is to use body hair, such as leg hair, although this approach fails when subjects do not possess leg hair with the appropriate characteristics or are simply uncomfortable with the transplantation of non-scalp

Dr Umar is a Clinical Instructor of Medicine, Division of Dermatology, Department of Medicine, University of California, Los Angeles (UCLA), Los Angeles, CA.

Corresponding Author:

Dr Sanusi Umar, FineTouch Dermatology, 819 North Harbor Drive, Suite 400, Redondo Beach, CA 90277, USA.
E-mail: drumar@dru.com

hair.² Swinehart used bisected hair follicles in an attempt to overcome the hair caliber issue, but this led to a significant reduction in yield (approximately 50%).¹

Nape and peri-auricular areas (NPA) offer a much wider selection of finer caliber hair as an alternative source for the reconstruction of softer hairlines and temples. However, this approach has not been exploited, largely because of concerns that NPA hairs lie outside of the traditional SDA and are thus nonpermanent. The assumption that all hair outside of the SDA is nonpermanent and likely to progress in many cases to a Norwood class 7 (NW7) hair loss is a fundamental premise of current hair transplant approaches.

The central premise of using only SDA hair for transplantation has been challenged by Unger, who reported that only 20% of 328 men aged 65 years and older had a NW7 level of hair loss.³ Because it is difficult to predict who will progress to a NW7 level of hair loss, it would be beneficial to have an assessment tool that can help distinguish whether use of hair outside of the SDA (such as from the NPA) may be viable. This is especially of potential value given that NPA hairs, which are of relatively thin calibers, have been mainly used for transplantation in situations requiring hair softness.⁴ There have been reports of this application in eyelashes and eyebrows, where they approximate nature more closely.⁵⁻⁷ However, these reports are rare and did not take into account possible future losses, possibly because they typically represented small areas of transplantation (ie, 50-300 grafts).⁵⁻⁷

Because the use of NPA hairs in the frontal hairline and temples is not that common, this article reports the author's experience (including patient satisfaction) in the use of NPA hair in the creation of soft hairlines in a patient population in which a simple test was used to exclude those likely to progress to a NW7 level of hair loss. A recipient grafting methodology that uses SDA to compensate for possible future loss of grafted NPA hair is also described.

METHODS

Informed consent was obtained from patients for surgery and the guidelines of the Department of Health and Human Services Regulations for the Protection of Human Subjects were followed. No IRB approval was sought because this was not a prospective or systematic investigation.

Study Design

Between November 2006 and November 2011, NPA hair by FUE transplantation was used as vanguard hairs for hairlines and temples in 128 male patients. Use of hair from the SDA was permitted behind the vanguard NPA hairs. No body hair was used. Between June 2011 and June 2012, a survey was sent to the patients to evaluate satisfaction with the procedure, restored hairline, and lost grafts. A follow-up survey was then sent to those patients who initially responded.

FUE Using NPA Hair

The extraction of NPA hair is similar to the eyebrow transplantation procedure previously reported.⁵

Patient Selection

Patients who are unlikely to lose their NPA hair over time are potentially ideal candidates for use of NPA hair for the creation of hairlines. To help in this evaluation, a "shave test" was performed. This test involved shaving the back and sides of the patient's head and NPA with a guardless clipper to a tight crew cut to evaluate a visible difference in hair density and caliber between areas that are permanent donors and areas that are nonpermanent donors. Patients were counseled during an initial consultation that nape hair would be used for their hairline if they were suitable candidates (otherwise body hair or conventional SDA hair could be used).

A patient that is not likely to lose NPA hair is one whose density and hair caliber spread is gradual, with no dramatic lines of demarcation (Figure 1A). In patients who are likely to lose their NPA and progress to NW7, there is a visible decline in density and hair caliber and a clear line of demarcation between what is traditionally described as the SDA and the non-SDA regions (Supplementary Figure 1A). Patients with these characteristics are not likely to be good candidates for the use of NPA hair for transplantation.

Based on the author's experience using the shave test, between 75% and 80% of patients will meet this selection criterion. After hair extraction from both the SDA and NPA, the results of patients who are good candidates for the use of NPA hair shows an even distribution of extraction wounds (Figure 1B). In contrast, for patients who are not considered good candidates based on the shave test, neck hair (if available) remains a viable option as it is not inhibited by dihydrotestosterone (DHT), unlike the NPA hair in such patients.⁸ Male pattern baldness is thought to result from dermal papilla cells secreting diffusible factors that subsequently affect follicular keratinocytes and dermal papilla cells in response to androgens (eg, DHT), possibly mediated by cytokines such as IL-6.^{9,10} However, hairs in the back and sides of the head typically sustain throughout life because they are DHT-resistant. While in the extreme condition of NW7 in which a wreath of hair is left behind, hair in the nape and periauricular areas is lost because DHT sensitivity affects the hairs in the nape and periauricular areas, this is not the case for the vast majority of balding patients because these areas are resistant to the actions of DHT.

Supplementary Figure 1B shows a patient who was not considered a good candidate for the use of NPA hair use and from whom hair was extracted from the neck below the NPA area. Long-term healing of the nape area after hair extraction usually proceeds without problems and results in no cosmetically significant scarring (Figure 1C).

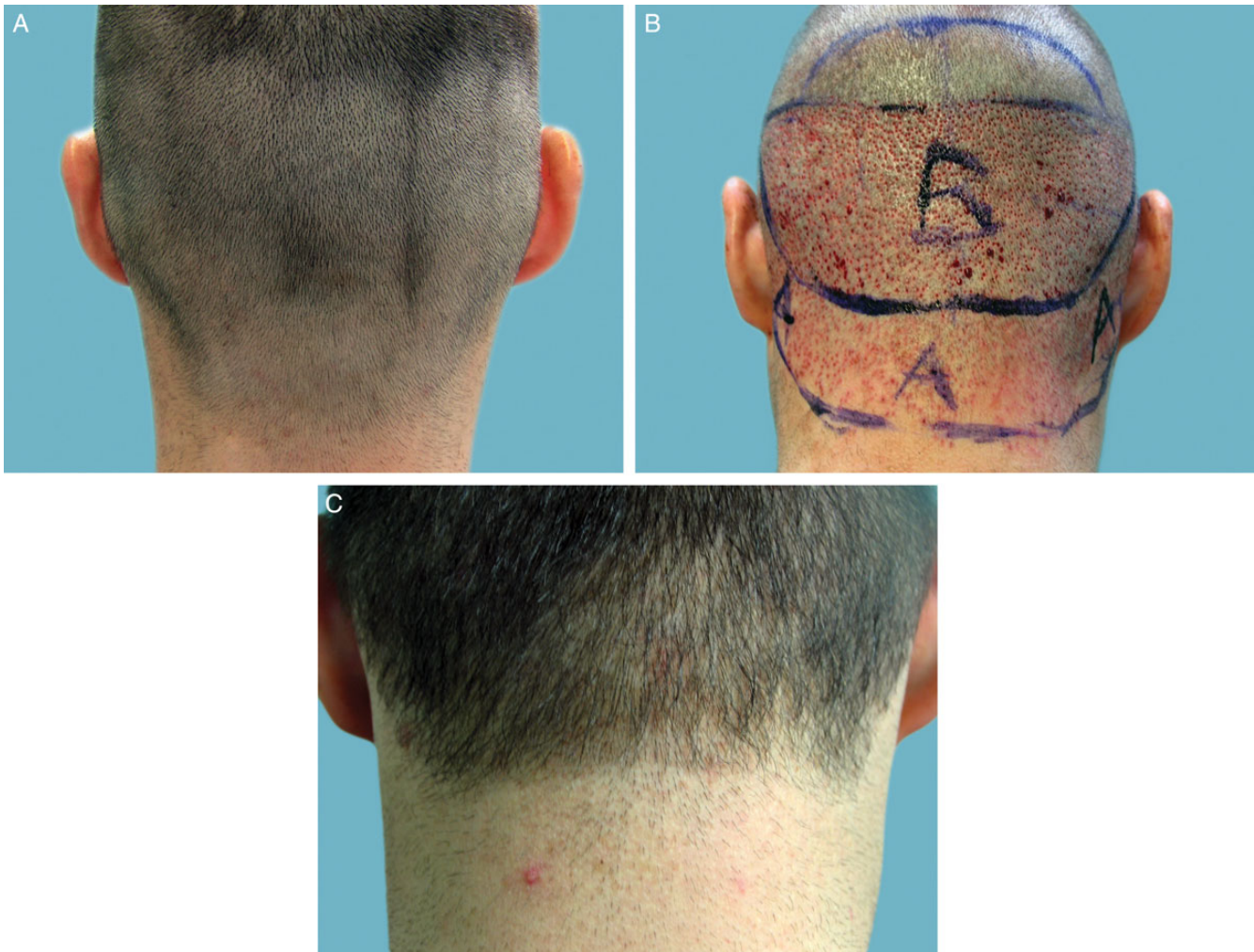

Figure 1. (A) Posterior donor area in a 32-year-old male candidate meeting the selection criteria for nape and peri-auricular (NPA) hair follicular unit extraction (FUE) after a shave test showing a visible gradual density and hair caliber spread. (B) FUE shown after hair extraction from both safe donor area (area marked B) and NPA area (area marked A); the extraction wound spread is uniform. (C) Image obtained 4 years postoperatively shows the nape area healed.

Donor and Recipient Area Planning

Figure 2 illustrates the recipient area implantation scheme and how SDA hair was integrated into the hairline in a manner that ensures that in the event of NPA hair loss, the resulting hairline should still remain within conventional standards. Healing of the nape hair extraction area leaves no cosmetically significant scarring, as can be observed from immediately after surgery to many years later (Supplementary Figure 2).

Because NPA hair tends to be of smaller caliber and lighter in color, the use of double follicles, even in the vanguard areas of the hairline, rarely results in a plugged look.

Transplantation Methodology

Hair transplantation was done using FUE under local anesthesia by subcutaneous injections of epinephrine (1:100,000)

and lidocaine 1%, and bupivacaine hydrochloride 0.25% without tumescence. A hypodermic needle was used with the tip modified so that its circumference is flared outward to form a punch-like instrument mounted on a rotary tool (UPunch Rotary, fabricated in the author's office in Redondo Beach, CA; Figure 3). This modification better enables an intact graft to be extracted because the axis of the punch cutting edges is directed away from the follicles, thus minimizing much of the customary graft damage that accompanies the use of straight punches.^{2,7} For the extraction, 19- or 18-gauge needles were used; smaller sizes than 19 gauge were not used to minimize traumatizing the NPA graft, which is weaker than SDA-derived grafts and more susceptible to damage. Larger gauge sizes than 18 were not used because this increases the likelihood of unsatisfactory scar sequelae.

Grafts were hydrated with a piece of gauze using a 2- to 3-minute interval between the time of scoring and the

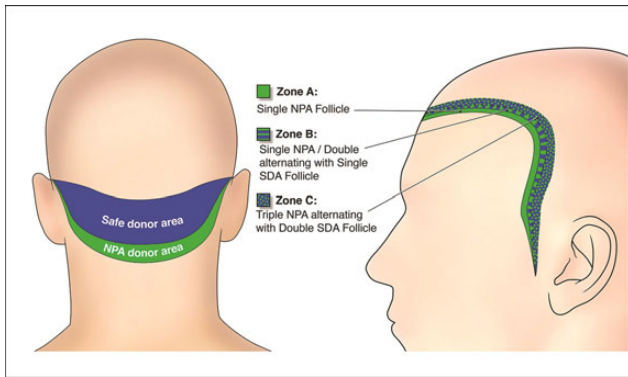


Figure 2. Donor area map (left) indicating the safe donor area (SDA) in blue and nape and peri-auricular (NPA) donor area in green, versus the recipient area map (right). On the recipient area map, Zone C indicates where the triple NPA follicles alternate with the double SDA follicles; Zone B indicates where the single NPA follicles (or double NPA follicles, when all singles are exhausted) alternate with the single SDA follicles; and Zone A indicates where the single NPA follicles are used.

actual removal of the follicles.² Currently, the author has automated this hydration phase of the procedure by the use of a device (UGraft Revolution prototype by Keck Craig, Inc., Pasadena, CA) that irrigates the grafts at the time of scoring.^{2,7} Hair follicles were then easily removed with the occasional assistance of hypodermic needle tip dissection and placed in chilled Ringer's lactate solution. As wounds created by these customized punches (Figure 3) widen with depth, injury to follicles is lessened and wound closure accelerated.² In the author's experience, an aggressive NPA harvest typically yields 500 to 750 grafts. For recipient grafting, slits were created by means of blades custom sized to the dimensions of the extracted grafts.

Patient Surveys

Following their surgeries, patients were e-mailed a questionnaire during June 2011 through June 2012 to assess their results and satisfaction with their procedure (all procedures were conducted from 2006 through 2011). The following indices were evaluated using 10- or 11- point Likert scales: healing status (0 = not well at all and 10 = very well); hair growth in the restored area (0 = no growth and 10 = excellent growth); overall satisfaction with the procedure and results (0 = not satisfied and 10 = extremely satisfied); hairline growth rate (1 = zero growth and 10 = excellent growth near 100%); time since surgery (months); time to see full postoperative hair results (months); softness of hairline (1 = very harsh and 10 = extremely soft); postoperative lost hair grafts (onset, months); and satisfaction with hairline (1 = no satisfaction and 10 = extremely satisfied). A blank copy of this questionnaire is available as Supplementary Material.



Figure 3. Inserts that are mounted on the rotary tool (UPunch Rotary, Redondo Beach, CA) showing tips of 18-gauge hypodermic needles modified with a flared edge so that the circular cut is directed away from the follicles in order to minimize customary graft damage.

From March 2014 to June 2014, a second questionnaire was e-mailed only to patients who responded to the first survey to assess their long-term results based on the following four variables: time since surgery (years); postoperative lost hair grafts (onset, years); postoperative estimated percentage of hair loss (%); and postoperative satisfaction (1 = no satisfaction and 10 = extremely satisfied). Additionally, the donor head count, donor nape count, and hairline recipient count were extracted from patient records and evaluated. A blank copy of this questionnaire is available as Supplementary Material.

RESULTS

From November 2006 through November 2011, 128 male patients underwent FUE hairline transplantation using NPA hair. All patients were e-mailed questionnaires. Mean follow-up time was 2.3 years (range, 0.6-5.1 years). Based on patient records, the mean patient age was 40.4 years (range, 23-54 years); the mean donor head count was 1600 follicles (range, 391-4500 follicles); the mean donor nape count was 500 follicles (range, 110-1800 follicles); and the mean hairline recipient count was 1400 follicles (range, 625-3136 follicles).

Ninety-one of 128 (71%) patients who underwent hairline restoration by FUE using NPA hair responded to the first survey (Table 1). The responses were obtained a mean (standard deviation [SD]) of 25.5 (12.70) months (range, 6-60 months) after their hair restoration procedures. The mean (SD) time patients reported observing their complete postoperative results (ie, full hair coverage in recipient area) was 9.6 (1.56) months (range, 4-18 months). Mean scores of 8 to 8.5 on a Likert-like scale of 0-10 or 1-10 were given by patients for their healing status (including

Table 1. Results of Patient Email Survey on Results and Satisfaction Following Neck and Peri-Auricular Follicular Unit Extraction Procedures Performed From November 2006 to November 2011

Survey Variable	n	Range	Mean	Standard Deviation
Healing Status (Donor Area, Scale of 0-10) ^a	76	4-10	8.4	1.63
Healing Status (Recipient Area, Scale of 0-10) ^a	77	4-10	8.5	1.63
Growth in Restored Area (Scale of 0-10) ^a	85	3-10	8.0	1.74
Overall Satisfaction (Scale of 0-10) ^a	82	3-10	8.3	1.62
Hairline Growth Rate (Scale of 1-10) ^a	62	3-10	8.3	1.56
Time Since Surgery (Months) ^a	67	6-60	25.5	12.70
Time to Postoperative Hair Results (Months) ^a	65	4-18	9.6	3.89
Softness of Hairline (Scale of 1-10) ^a	65	4-10	8.0	1.77
Postoperative Lost Grafts (Onset, Months) ^a	59 ^b	1-36	10.2	8.04
Satisfaction with Hairline (Scale of 1-10) ^a	64	4-10	8.5	1.38

^aResponses from the first survey, conducted from June 2011 through June 2012 (response rate: 75.7%, n = 97).

^b40 patients (67.8%) reported no problems; data are for patients who reported problems (n = 19, 32.2%).

healing of the donor area), hair growth in the recipient area, and overall satisfaction with their hair restoration procedure. For lost hair grafts, 59 patients (46% of all patients) responded, and 40 patients (68% of the responders) reported no graft loss. Lost grafts were noted by 19 patients at a mean (SD) of 10.2 (8.04) months following their surgeries.

Patients responding to the survey reported overall that they were very satisfied with hairline results, giving a mean (SD) score of 8.5 (1.38; range, 4-10). The natural softness of the hairline was also graded highly. Figure 4 depicts a patient's preoperative and postoperative hairline results. In Figure 4A, the hairline rows are shown preoperatively: 1000 grafts were used to simulate a NW3 recessed hairline using the methodology explained in Figure 2. Figure 4B shows the same patient 2 years after his NPA FUE hairline procedure. The hairline looks soft and natural and is a good example of the results reported by most patients. Figure 5 and Supplementary Figure 3 were selected to show two other patients with similar results.

Of 91 patients who responded to the initial questionnaire, only 33 (36%) responded to a second follow-up questionnaire conducted briefly from March 2014 to June 2014. For these patients, the mean time after their surgeries at the time of the survey was 4.6 years, with an overall patient satisfaction mean of 8.5 (Table 2). Only 9 of 33 responders (27%) reported losing grafts over this same period of time, with 5 of these 9 respondents losing grafts from the onset (Table 2). Based on data from 8 patients, it was estimated that mean hair loss was 24% in the recipient area. In some of these patients, the area of graft loss involved transplants from both the NPA and SDA.

DISCUSSION

Many patients are candidates for the use of NPA hair to create soft-appearing hairlines using the shave test, which is a quick, inexpensive, and effective way to determine permanent versus nonpermanent donor areas. In patients who are likely to lose their NPA hair and progress to NW7, this test reveals a line of demarcation between the SDA and non-SDA. In addition, patients seem to tolerate FUE procedures better when minimal shaving is involved, as it allows a faster return to normal social activities (shaving is restricted to the NPA areas in patients requiring minimal hairline work). Despite the limitation of retrospective surveys being based on self-selection of responders, approximately 70% of 128 transplanted patients responded and reported high levels of satisfaction with their results.

Patients noted completed results with full hair coverage in their restored area a mean of 9.6 months after their surgeries, which is similar to results reported for transplanted non-head hair.² Nape and periauricular areas are typically healed to pleasing aesthetic ends by the sixth week to the third month. Occasionally, tiny white dots have occurred that were deemed cosmetically insignificant by the patients: these dots are in line with wounds typically created by the FUE procedure in SDA areas and have not been a source of patient complaints in the author's experience.² Niches for NPA exist not only in repairing transplanted frontal and temple hairlines that were created using coarse SDA hair or old-fashioned multi-hair plugs, but also in women, since female hairlines are naturally much softer in the vanguard areas. Another useful application is in certain racial demographics, such as Asians, whose scalp hair is coarser on

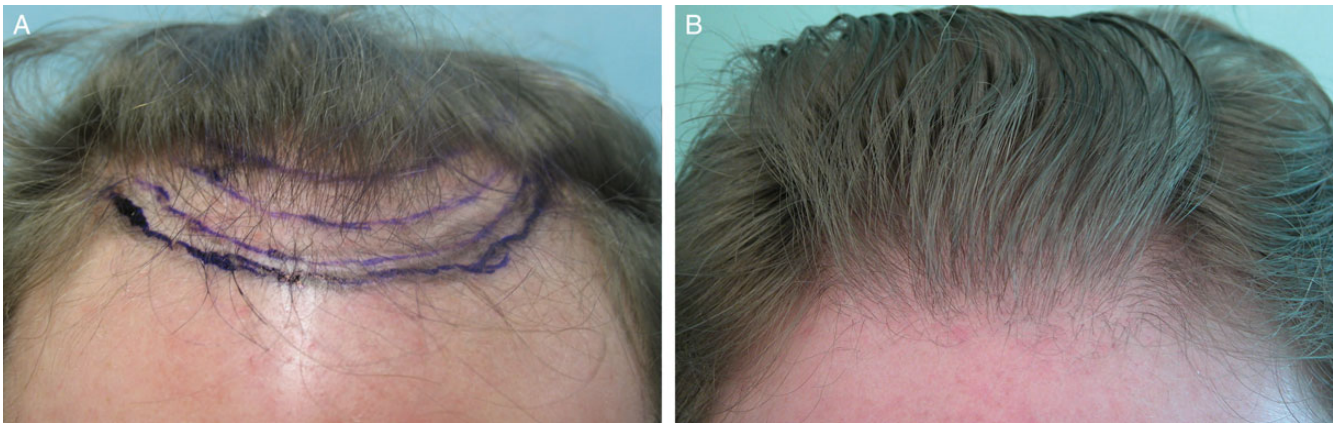


Figure 4. (A) A 47-year-old male patient's hairline before restoration using nape and peri-auricular (NPA) hair. (B) The patient's hairline 2 years postoperatively after a hair transplant procedure using 1000 grafts, mostly derived from the NPA, to simulate a Norwood 3 recessed hairline.

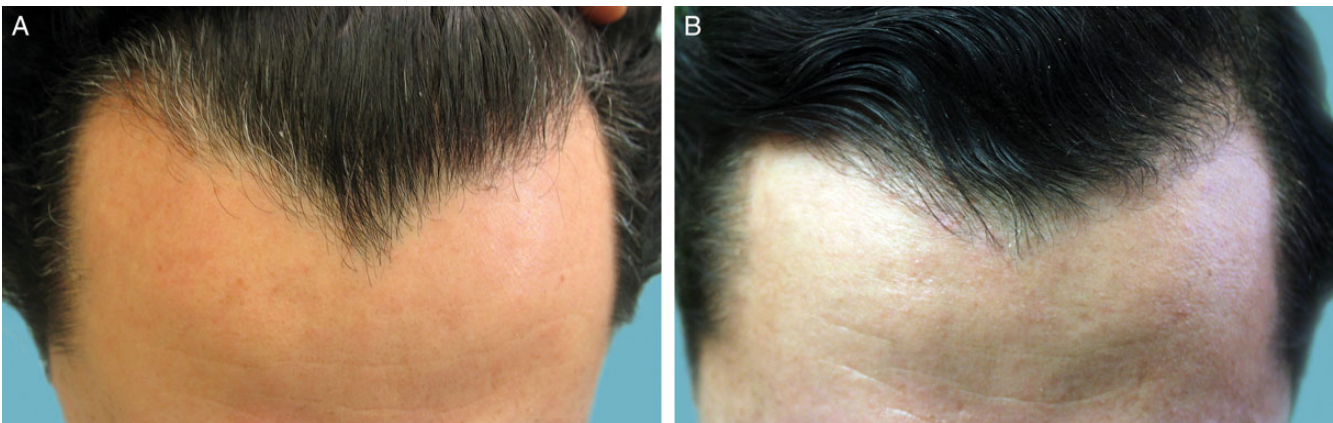


Figure 5. (A) A 39-year-old male patient's hairline before restoration with nape and peri-auricular (NPA) hair to remedy a "Dracula" pattern. (B) The patient's hairline 5 years postoperatively after hair transplantation with 600 NPA-derived hair grafts.

Table 2. Results of Second Patient Email Survey Regarding Graft Retention and Satisfaction Following Nape and Peri-Auricular Follicular Unit Extraction Procedures Performed From November 2006 to November 2011.

Survey Variable	n	Range	Mean	Standard Deviation
Time Since Surgery (Years)	29/33	3-6	4.6	0.756
Postoperative Lost Grafts (Onset, Years) ^a	5 ^a	0.5-5	1.6	0.822
Postoperative Estimated Percentage of Loss	8	13-50	24	12.67
Postoperative Satisfaction (Scale of 1-10)	28	1-10	8.5	1.93

March 2014 through June 2014; n = 33 respondents. ^a24 patients (73%) reported no problems; 9 patients (26%) reported problems.

average.¹¹⁻¹³ Patients reported being very satisfied with healing, including the donor areas.

Based on patient data from the second survey, albeit a small sample, it was estimated that a minority of patients with long-term follow-up lost transplanted grafts and, when this occurred, there was a 75% graft survival rate. This is a significant improvement over the poor yield of 50% reported by Swinehart,¹ who used bisected follicles. Additionally, some of the grafts lost were in areas that involved hair from the SDA, which is consistent with findings by Park et al¹⁴ showing that graft loss can occur even in SDA-only transplants. It would take a larger study and a follow-up survey longer than the mean 4.6 years in this report to warrant a conclusive statement on long-term graft survival. To compensate for this, SDA hair was incorporated into the hairlines and temples for patients in a manner that leaves the patient

with a conventionally transplanted hairline and temple look in the event that some grafts from the NPA are eventually lost. The ability to preselect patients who may be the best responders and the relatively high rate of satisfaction among patients answering a retrospective survey supports a role for NPA-derived follicles in FUE hair transplantation to create softer hairlines.

There are some limitations to this study. First, non-validated surveys were used, which can result in some response bias. Second, patients are recalling satisfaction in some instances over long periods of time, which could be inaccurate. Third, missing data on parameters could have caused an over- or underestimate in regard to means and variance estimates. Fourth, questionnaires were not sent via email anonymously, which might have caused some bias in replies. Finally, because this study was not a cohort type of design following a group of subjects over a fixed period of time, there is likely to be some bias in the results, especially on reporting events over many years.

CONCLUSIONS

Soft, natural-looking hairlines can be created in patients using NPA hair as a donor source by FUE hair transplantation, but selection of good candidates is paramount to obtain satisfactory, long-lasting results. The final aesthetic appearance takes 6 to 12 months following surgery and, in a few cases, about a quarter of the transplanted grafts can be lost over several years.

Supplementary Material

This article contains supplementary material located online at www.aestheticsurgeryjournal.com.

Acknowledgments

The author created the concept for Figure 2, which was rendered by Sean Prokasy of MedVisuals, Inc., (Dallas, TX), who provided permission to include it with this article.

Disclosures

The author has applied for a patent for the rotary tool described in this article as used for graft extraction.

Funding

The author received no financial support for the research, authorship, and publication of this article.

REFERENCES

1. Swinehart JM. "Cloned" hairlines: the use of bisected hair follicles to create finer hairlines. *Dermatol Surg*. 2001;27:868-872.
2. Umar S. Use of body hair and beard hair in hair restoration. *Facial Plast Surg Clin North Am*. 2013;21:469-477.
3. Unger W, Cole J. The donor area. In: Unger W, Shapiro R, eds. *Hair Transplantation*. 4th ed. New York: Marcel Dekker; 2004:301-337.
4. Harris J. Conventional FUE. In: Unger W, Shapiro R, Unger R, eds. *Hair Transplantation*. 5th ed. London: Informa Healthcare; 2011: 291-298.
5. Umar S. Eyebrow transplants: The use of nape and peri-auricular hair in six patients. *Dermatol Surg*. 2014;40: 1416-1418.
6. Gandelman M. A Technique for reconstruction of eyebrows and eyelashes. *Semin Plast Surg*. 2005;19:153-158.
7. Umar S. Eyelash transplantation using leg hair by follicular unit extraction. *Plast Reconstr Surg Glob Open*. 2015;3:e324.
8. Kaufman KD. Androgens and alopecia. *Mol Cell Endocrinol*. 2002;198:89-95.
9. Randall VA. Androgens and hair growth. *Dermatol Ther*. 2008;21:314-328.
10. Kwack MH, Ahn JS, Kim MK, Kim JC, Sung YK. Dihydrotestosterone-inducible IL-6 inhibits elongation of human hair shafts by suppressing matrix cell proliferation and promotes regression of hair follicles in mice. *J Invest Dermatol*. 2012;132:43-49.
11. Umar S. Hair transplantation in patients with inadequate head donor supply using nonhead hair: report of 3 cases. *Ann Plast Surg*. 2011;67:322-325.
12. Franbourg A, Hallegot P, Baltenneck F, Toutain C, Leroy F. Current research on ethnic hair. *J Am Acad Dermatol*. 2003;48(Supp 6):S115-S119.
13. Takahashi T, Hayashi R, Okamoto M, Inoue S. Morphology and properties of Asian and Caucasian hair. *J Cosmet Sci*. 2006;57:327-338.
14. Park JH, Na YC, Moh JS, Lee SY, You SH. Predicting the permanent safe donor area for hair transplantation in Koreans with male pattern baldness according to the position of the parietal whorl. *Arch Plast Surg*. 2014;41: 277-284.